



PATIENT PRESENTING CLINICAL SIGNS

Sophie Klemmedson Sophie presented to TSVC for concern of a broken jaw/trauma to the lower jaw. She was found by owners outside excessively bleeding from the mouth and broken mandibular incisors. Incident occurred this morning around 8am.

SPECIES

Canine

Abnormal PE/Chem/CBC/UA Results: Pre-operative bloodwork was unremarkable. Contrast (1.3ml/lb) 117ml total IV

BREED

Golden Retriever

COMPUTED TOMOGRAPHIC STUDY OF THE HEAD

Plain and post contrast studies are available for review.

COMPUTED TOMOGRAPHIC FINDINGS

SEX

Compound fractures of the bilateral rostral mandibles with bilateral horizontal main fracture lines in the rostral mandibles is seen as well as a transverse fracture of the right rostral mandible.

FS

The area of the osseous injury involves all incisors of the right and left mandible with multicentral displacement as well as the alveolus of the 304 and 404 and the alveolus and roots of 405 and 406.

AGE

Complicated crown fractures of all canine teeth are seen.

6yr

No symphyseal displacement is noted. The general mandibular alignment appears to be preserved except for the area for the incisor areas of the right and left rostral mandibles. The mandibular rami are intact.

INTERPRETED BY

Nele Eley (Ondreka),
DVM Dr. med. vet.,
DipECVDI

Bilateral temporomandibular joints are intact with normal articular alignment.

Mild gas inclusions are noted within the areas of the fracture of the rostral mandibular suggesting open fractures.

HOSPITAL NAME

No maxillary fractures are identified.

Scottsdale Veterinary
Clinic

COMPUTED TOMOGRAPHIC DIAGNOSIS

- Acute traumatic open bilateral rostral mandibular fractures
- Complicated crown fractures of all canine teeth
- Dental involvement: all right and left mandibular incisors 304 404 405 406.

REFERRING VET

Dr Rodrick

INTERPRETATION OF FINDINGS & FURTHER RECOMMENDATIONS

INVOICE

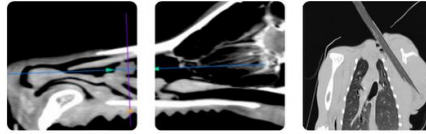
22916

The CT study reveals acute bilateral open rostral mandibular fractures with more extensive involvement on the right side affecting multiple incisors and alveoli including 301 through 304 and 401 through 406. Complicated crown fractures of all canine teeth are seen. The rostral mandibular fracture is considered open and may be infected. The mandibular rami and temporomandibular joints are intact. No maxillary bone involvement is seen. Symphyseal alignment appears to be preserved.

DATE

11/08/2025

Consider surgical stabilization, bilateral fixation appears indicated along with dental management



PATIENT

Sophie Klemmedson

with either treatment or extraction of the affected teeth. Antibiotic treatment should be considered as per standard post-traumatic management for open oral fractures.

SPECIES

Canine

BREED

Golden Retriever

SEX

FS

AGE

6yr

INTERPRETED BY

Nele Eley (Ondreka),
DVM Dr. med. vet.,
DipECVDI

HOSPITAL NAME

Scottsdale Veterinary
Clinic

REFERRING VET

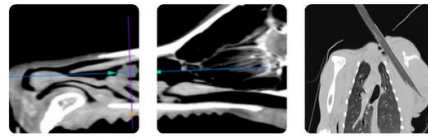
Dr Rodrick

INVOICE

22916

DATE

11/08/2025



PATIENT

Sophie Klemmedson

SPECIES

Canine

BREED

Golden Retriever

SEX

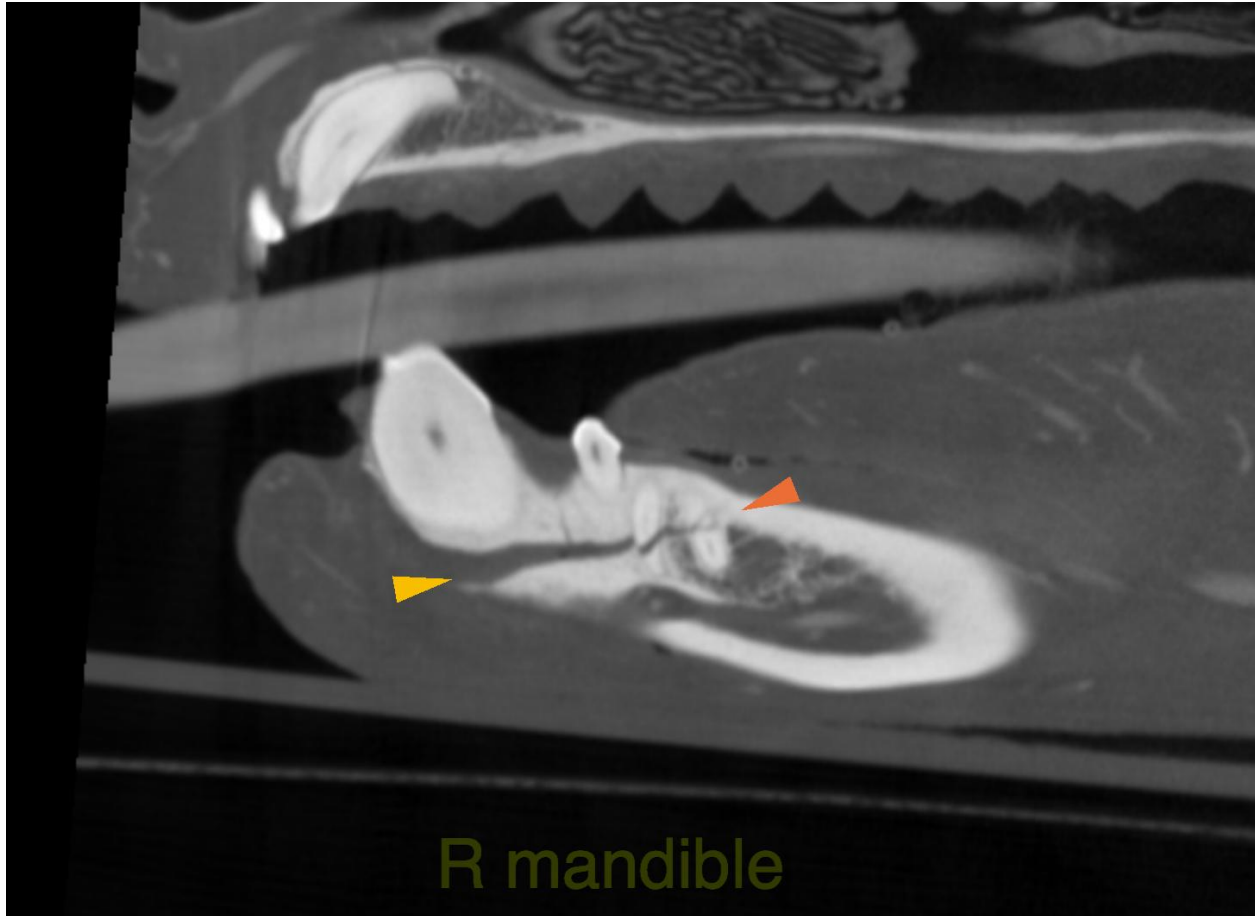
FS

AGE

6yr

INTERPRETED BY

Nele Eley (Ondreka),
DVM Dr. med. vet.,
DipECVDI



R mandible

HOSPITAL NAME

Scottsdale Veterinary
Clinic

REFERRING VET

Dr Rodrick

INVOICE

22916

DATE

11/08/2025



PATIENT

Sophie Klemmedson

SPECIES

Canine

BREED

Golden Retriever

SEX

FS

AGE

6yr

INTERPRETED BY

Nele Eley (Ondreka),
DVM Dr. med. vet.,
DipECVDI

HOSPITAL NAME

Scottsdale Veterinary
Clinic

REFERRING VET

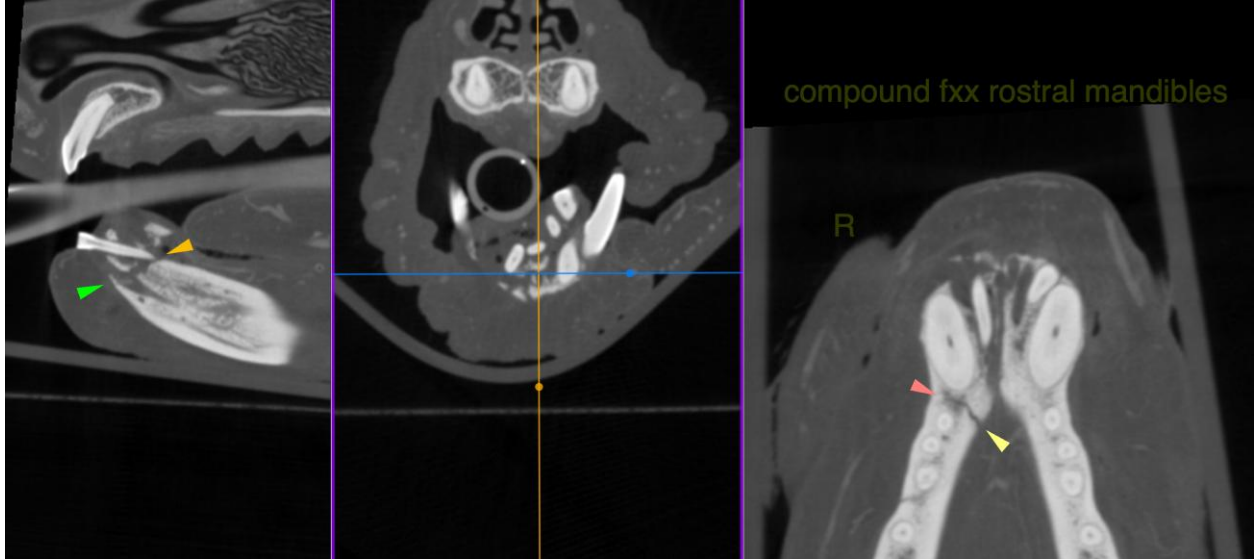
Dr Rodrick

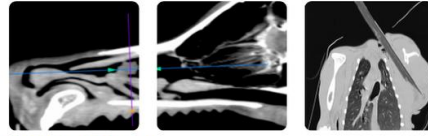
INVOICE

22916

DATE

11/08/2025





PATIENT

Sophie Klemmedson

The information and recommendations provided are based on the images presented by the referring veterinarian. No evaluation can be communicated regarding pathology that was not visible in the image/video clips provided.

SPECIES

Canine

Thank you for this referral. If the clinical or image interpretation does not parallel your findings or if I can be of any further assistance please contact me.

BREED

Golden Retriever

Nele Eley (Ondreka), DVM, Dr. med. vet., DipECVDI
European Specialist in Veterinary Diagnostic Imaging, Cert. Radiology,
Senior lecturer University of Giessen/Germany, Veterinary Faculty, Department of Radiology.
info@sonopath.com

SEX

FS

AGE

6yr

INTERPRETED BY

Nele Eley (Ondreka),
DVM Dr. med. vet.,
DipECVDI

HOSPITAL NAME

Scottsdale Veterinary
Clinic

REFERRING VET

Dr Rodrick

INVOICE

22916

DATE

11/08/2025